

# Y-Scar Vertical Mammoplasty

David A. Hidalgo, M.D.

*New York, N.Y.*

**Background:** Vertical mammoplasty is an effective alternative to inverted-T methods. Among other benefits, it results in a significantly reduced scar pattern. There exists a subset of patients with mild macromastia and minimal ptosis who are candidates for a scar pattern that is further reduced. These patients are usually young and have limited enlargement of the areolae. The upper half of the circumareolar incision can be deleted in these patients to result in a Y-shaped scar pattern. This technique is also applicable to some patients seeking mastopexy with augmentation.

**Methods:** Ten patients meeting the criteria described were treated with Y-scar vertical mammoplasty and were reviewed retrospectively.

**Results:** Eight patients had breast reduction or mastopexy and two patients had mastopexy with augmentation. The average amount of tissue removed from each breast in the reduction group was 198 g (range, 76 to 382 g). The average follow-up period was 8.4 months. Problems encountered were minor and included inferior areolar fullness in three patients and an inverted nipple in one patient. One patient developed a unilateral lower pole deformity several months after surgery that required corrective surgery. All patients were pleased with their final surgical outcome.

**Conclusions:** The Y-shaped scar incision design is useful in appropriate candidates to further reduce the scar burden associated with vertical mammoplasty. Retaining the normal transition from pigmented areolar skin to adjacent lighter skin in the upper half of the areola significantly reduces the perception of the overall scar pattern. (*Plast. Reconstr. Surg.* 120: 1749, 2007.)

Vertical mammoplasty has been developed into a viable alternative to inverted-T methods, although certain problems have discouraged widespread use.<sup>1-7</sup> However, recent technical refinements have made it possible to eliminate these concerns to make the procedure a much more attractive option.<sup>8,9</sup>

There exists a subset of patients with minimal conditions for whom even vertical mammoplasty would create an excessive scar burden. These are very young breast reduction candidates that have minimal or no ptosis, mild macromastia, and excellent skin elasticity. Although uncommon, they can be treated by posterior parenchymal resection through a limited inframammary crease incision because there is little excess skin and no need to elevate the nipple position.<sup>10,11</sup> Their skin contracts effectively postoperatively to contribute to achieving ex-

cellent results. The rare much older patient with similar breast characteristics can be effectively treated with liposuction alone because of the higher fat content in the breast.

There is another subset of breast reduction candidates who are not suitable for the posterior parenchymal excision method because of slightly greater ptosis but who also do not need a complete vertical scar pattern. These patients are young (or older but nulliparous), have no more than grade I ptosis, have aesthetically acceptable areolar diameter, and have generally mild macromastia. Because closure of the splayed vertical limbs drawn as part of the vertical reduction skin design automatically elevates nipple position,<sup>8</sup> it is superfluous to make the upper half of the circumareolar incision in these patients. This Y-shaped scar pattern vertical mammoplasty accomplishes as much as a complete vertical scar pattern but with less total scar. It can also be applied to some augmentation-mastopexy candidates.

## PATIENTS AND METHODS

Ten patients who were suitable candidates for this technique were reviewed retrospectively.

*From the Division of Plastic Surgery, Weill-Cornell University Medical College.*

*Received for publication August 29, 2006; accepted October 24, 2006.*

*Copyright ©2007 by the American Society of Plastic Surgeons*

DOI: 10.1097/01.prs.0000287129.47374.84

Those undergoing breast reduction had a vertical skin incision design drawn on the breast that begins by manually displacing the breast from side to side, drawing vertical limbs that will become the new breast meridian when approximated.<sup>8</sup> The breast is then lifted and these limbs are continued inferiorly, curving them to converge at a point approximately 1 to 2 cm above the inframammary crease. The vertical limbs continue superiorly as high as the inferior areolar margin, where the incisions then follow the areolar margin on each side to the 9-o'clock and 3-o'clock positions. Patients undergoing mastopexy with augmentation are first augmented with a breast sizer placed in a subpectoral plane through a standard periareolar incision. They are then placed in a sitting position and a vertical skin design is drawn by displacing the breast in a fashion similar to that used for the reduction group. Trial suture of the skin design is then performed to achieve optimal lower pole contour. This sometimes requires curving the top portion of the vertical limbs slightly inward toward each other to avoid a pinching deformity of the lower pole just below the areola. The sizer is then adjusted as needed to determine optimal implant volume.

The tissue between the vertical limbs is excised, leaving a substantial tongue of breast tissue extending at least 2 to 3 cm below the inferior areolar margin in the reduction patients. No tissue is excised between the vertical limbs in the mastopexy with augmentation patients because previous experience revealed that excision of lower pole tissue can lead to either implant exposure through suture sinuses or lower pole shape problems. The latter is because of inadequate soft-tissue volume to maintain the shape of the lower pole against scar contraction forces along the vertical scar.<sup>8</sup> The incised periareolar skin is mobilized in both groups of patients to allow closure of

the vertical incision with minimal distortion of the lower areola.

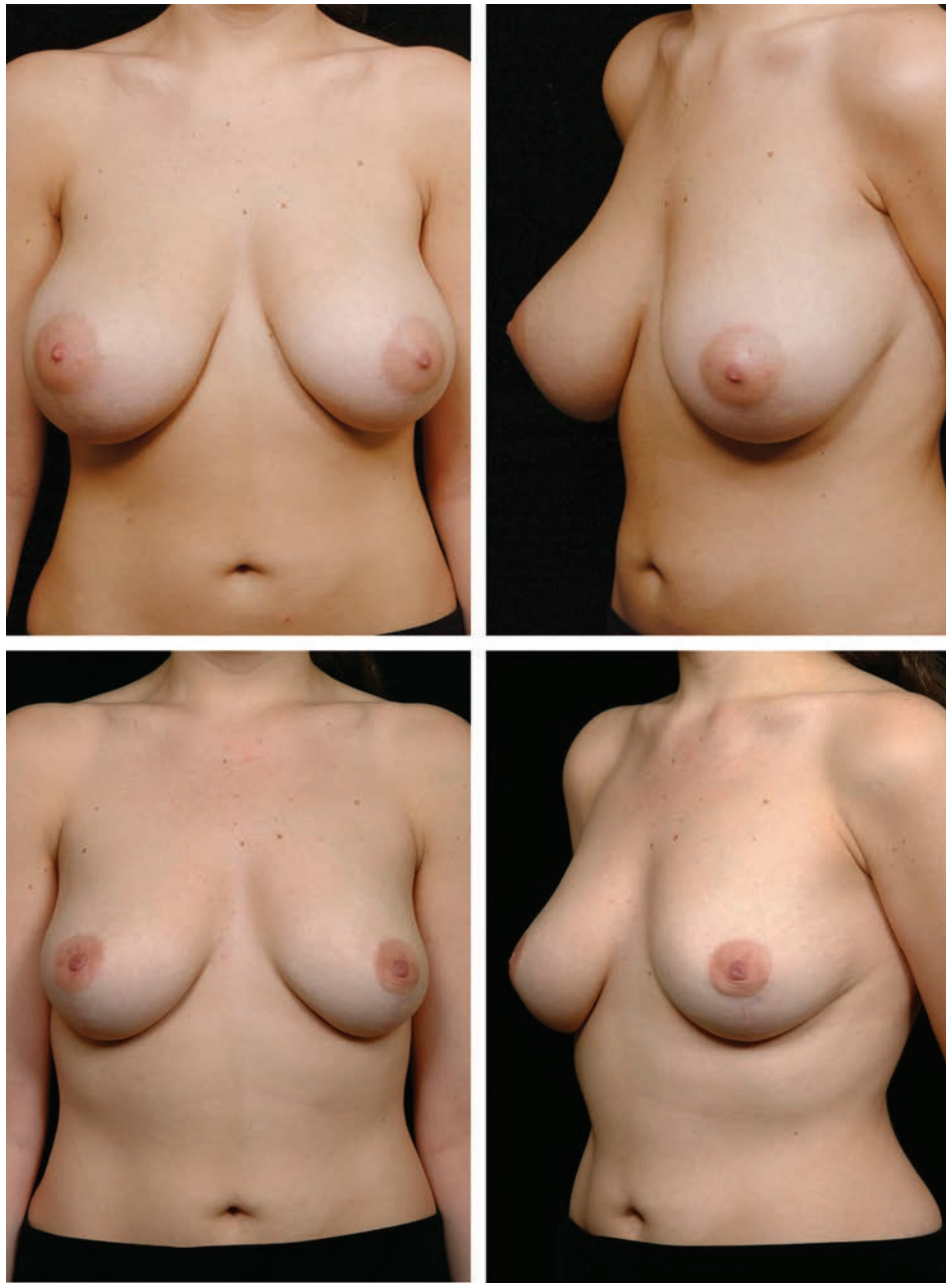
Medial and lateral excision of breast tissue in the reduction group is performed in the same fashion as conventional vertical reduction, creating medial and lateral pillars that remain attached to both the chest wall and overlying skin. Closure of the pillars is performed after placing a drain through a separate incision. Pillar closure helps to maintain the central vertical dimension of the breast and thereby prevent lower pole flattening. The superior pedicle with its 2- to 3-cm infraareolar extension rests on top of the pillars to help create an "I beam" structure that also contributes to preservation of the central vertical dimension of the breast.<sup>8</sup>

After the vertical incision is closed, the areolar shape is adjusted by excising small crescents of skin as needed to restore a round shape to the inferior areola. It was noted in some reduction patients that the inferior half of the areola would bulge outward, yielding a shape reminiscent of a tuberous breast areola. This required careful debulking of pedicle tissue to eliminate this appearance. This must be performed cautiously, because overly aggressive debulking of the infraareolar pedicle extension can lead to late infraareolar depression when healing is complete.<sup>8</sup> This bulging lower areola phenomenon has not been seen in conventional vertical reduction with a complete circumareolar incision.

Wound closure resulted in an inverted nipple in one patient with minimally protuberant nipples to begin with. This has also been seen occasionally in complete circumareolar incision vertical reduction and is therefore not unique to the Y-scar method. The nipple should be stented by suturing it to a shortened 20-cc syringe barrel affixed to the skin if this development is observed intraoperatively.

**Table 1. Patient Characteristics**

Patient	Age (yr)	Follow-Up (mo)	Reduction Volume (g)		Implant Volume		Bra Size	
			Left	Right	Left	Right	Preoperative	Postoperative
1	22	13	270	270	—	—	34DDD	34C
2	17	10	287	203	—	—	34DD-E	34D
3	36	13	150	136	—	—	36DD	36C/D
4	42	3	—	—	125	125	34C	34C
5	24	14	228	332	—	—	32DD	32C
6	37	1	76	96	—	—	36DD	34C/36B
7	49	2	46	120	—	—	34DD	34D
8	25	5	182	164	—	—	34D	34C
9	20	16	380	382	—	—	32D/DD	32C
10	46	7	—	—	125	150	34B	34C-D



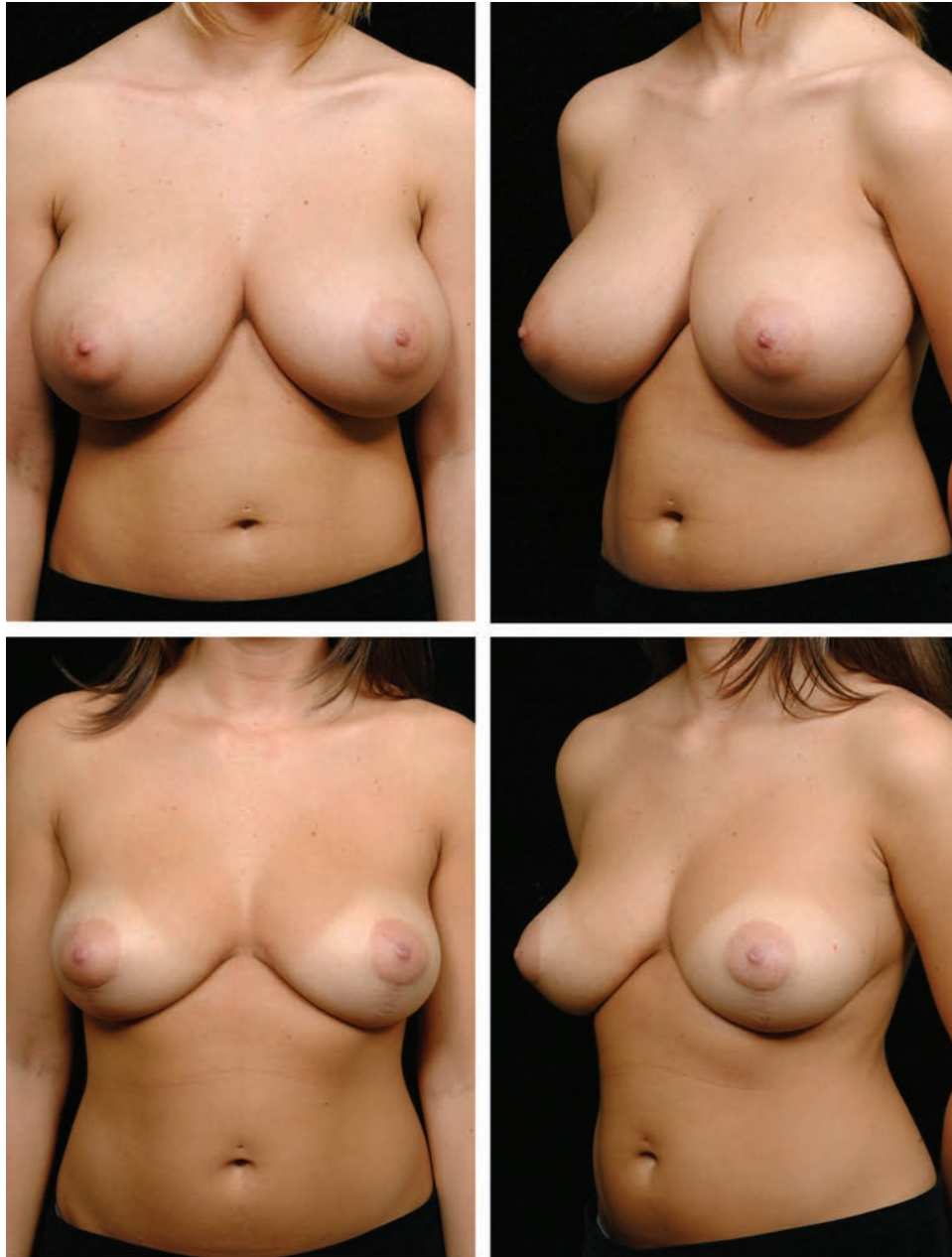
**Fig. 1.** Y-scar reduction. (Above) Preoperative views of a 24-year-old patient with a 32DD bra size. (Below) Postoperative views at 14 months. On the right side, 332 g of breast tissue was removed; on left side, 228 g was removed.

The patient should be observed completely upright to check nipple position before final closure of the areola. This sometimes requires a small amount of reverse Trendelenburg position added to maximum back elevation of the operating table to achieve the correct position to make this judgment. If the nipple position is low, it is a simple matter to convert to a complete circumareolar incision pattern. A small amount of skin is excised

superiorly and the areola adjusted upward to improve nipple position.

### RESULTS

Eight patients had breast reductions, and two patients had mastopexy with augmentation (Table 1). The average amount of tissue removed from each breast in the reduction group was 198 g (range, 76 to 382 g). The average follow-up period



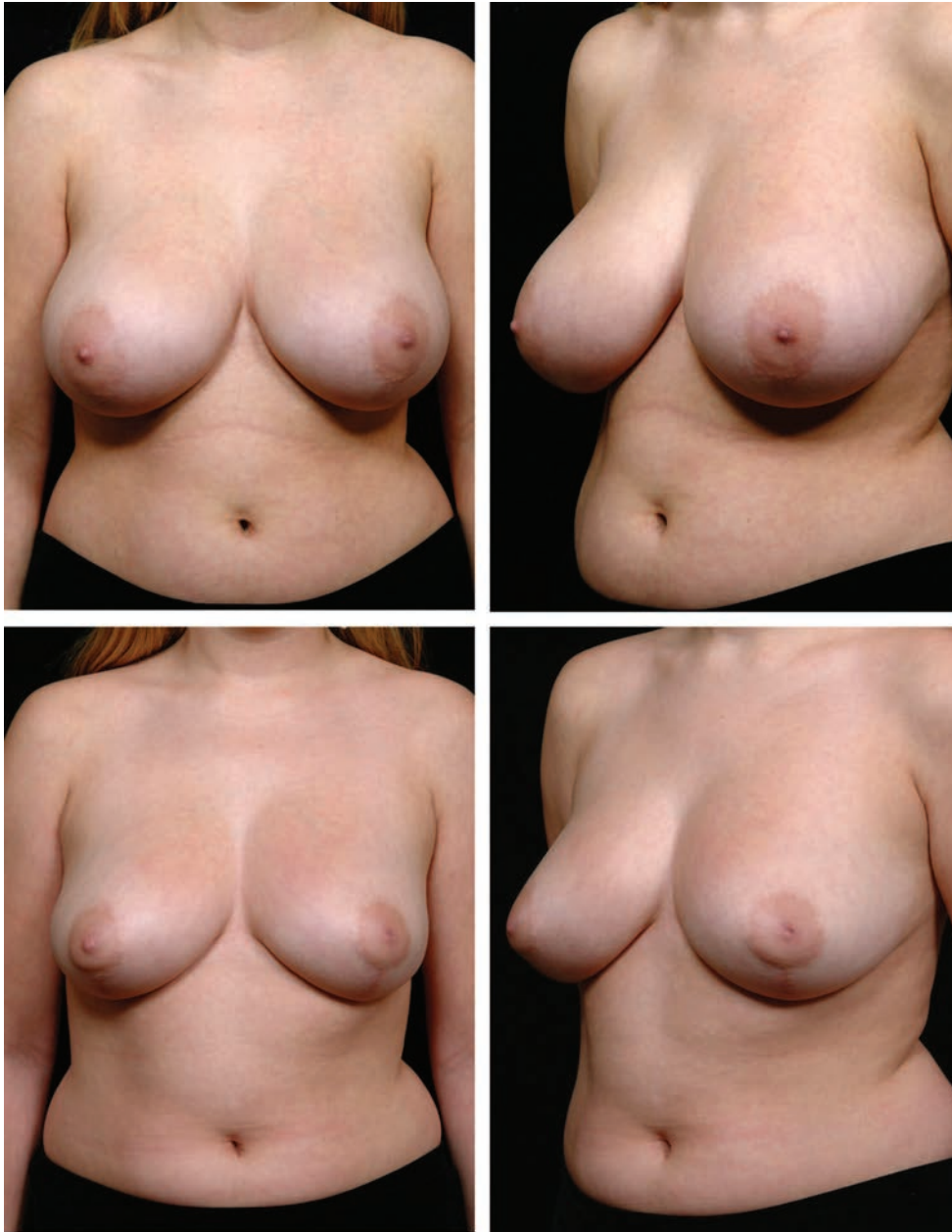
**Fig. 2.** Y-scar reduction. (Above) Preoperative views of a 20-year-old patient with a 32DD bra size. (Below) Postoperative views at 16 months. On the right side, 382 g of breast tissue was removed; on the left side, 380 g was removed.

was 8.4 months. There were no implant-related problems. Minor inferior areolar fullness occurred in three patients, and an inverted nipple occurred in one patient. The latter patient required external stenting of the nipples beginning 10 days after surgery to correct the problem. One patient developed a lower pole deformity several months after surgery that required corrective surgery. A small seroma bursa was excised in this

patient. Release of the associated scar tissue restored lower pole contour. All patients were pleased with their final surgical outcome. Representative patient examples are shown in Figures 1 through 3.

### DISCUSSION

Vertical mammoplasty has been a significant advance in reducing the scar burden associated



**Fig. 3.** Y-scar reduction. (Above) Preoperative views of a 22-year-old patient with a 34DDD bra size. (Below) Postoperative views at 13 months after 270 g of breast tissue was removed on each side.

with both reduction mammoplasty and mastopexy with augmentation. Other techniques such as liposuction-only reduction and “deaugmentation” reduction mammoplasty are even better in this regard but unfortunately are not widely applicable. The Y-scar mammoplasty described in this report allows the observant surgeon an opportunity to reduce the vertical mammoplasty scar pattern further in appropriate candidates. Retaining the normal transition from pigmented areolar skin to adjacent lighter skin in the upper half of the areola

significantly reduces the perception of the overall scar pattern. This makes this variation of vertical mammoplasty technique a worthwhile method.

*David A. Hidalgo, M.D.*  
655 Park Avenue  
New York, N.Y. 10021  
hidalgod@drdavidhidalgo.com

#### **DISCLOSURE**

*The author has no conflicts of interest regarding any of the material presented in this article.*

## REFERENCES

1. Hall-Findlay, E. J. A simplified vertical reduction mammoplasty: Shortening the learning curve. *Plast. Reconstr. Surg.* 104: 748, 1999.
2. Lassus, C. A technique for breast reduction. *Int. Surg.* 53: 69, 1970.
3. Lassus, C. Breast reduction: Evolution of a technique. A single vertical scar. *Aesthetic Plast. Surg.* 11: 107, 1987.
4. Lejour, M. Vertical mammoplasty and liposuction of the breast. *Plast. Reconstr. Surg.* 94: 100, 1994.
5. Lejour, M. *Vertical Mammoplasty and Liposuction of the Breast*. St. Louis: Quality Medical Publishing, 1994.
6. Lejour, M., and Abboud, M. Vertical mammoplasty without inframammary scar and with breast liposuction. *Perspect. Plast. Surg.* 4: 67, 1990.
7. Lejour, M. Vertical mammoplasty: Early complications after 250 personal consecutive cases. *Plast. Reconstr. Surg.* 104: 764, 1999.
8. Hidalgo, D. A. Vertical mammoplasty. *Plast. Reconstr. Surg.* 115: 1179, 2005.
9. Iqbal, A., and Ellabban, M. G. Vertical scar reduction mammoplasty refinements (Letter). *Plast. Reconstr. Surg.* 115: 977, 2005.
10. Hidalgo, D., and Hirmand, H. Deaugmentation reduction mammoplasty. *Aesthetic Surg. J.* 24: 112, 2004.
11. Corduff, N., and Taylor, G. I. Subglandular breast reduction: The evolution of a minimal scar approach to breast reduction. *Plast. Reconstr. Surg.* 113: 175, 2004.

## Online CME Collections

*Plastic and Reconstructive Surgery* is pleased to offer you Online CME Collections. Each collection represents a number of CME articles published in the *Journal*. **These articles are suitable for use as study guides for board certification, to help readers re-familiarize themselves on a particular topic, or to serve as useful reference articles. Articles less than 3 years old can be taken for CME credit.**

Articles are grouped in the following compilations:

- According to year of publication (14 articles/collection)
  - 7 complete collections, 1999 to 2005
  - 1 collection in process, 2006
- By topic (articles through October of 2006)
  - Breast (9 articles)
  - Cosmetic (17 articles)
  - Hand/Peripheral Nerve (13 articles)
  - Pediatric/Craniofacial (26 articles)
  - Reconstructive–Head and Neck (20 articles)
  - Reconstructive–Trunk (15 articles)
  - Reconstructive–Lower Extremity (5 articles)

### Article Format

The CME articles reflect the evolution of online presentation: CME articles from 1999 are viewable in HTML format only. All CME articles from 2000 onward are in PDF format. All articles can be printed out if desired.

### Tests

All CME articles from 1999 to 2003 have the tests included at the end of the article. These CMEs cannot be taken for credit. Answer keys are not available, but answers to every question can be found within the article.

All CME articles less than 3 years old (beginning with the January 2004 CME article) are still “active”; their tests can be taken for CME credit. Tests for these CME articles can be found on the *Journal* Web site, under the “Online CME Articles/Tests” link. If you have not yet taken these CME tests, we encourage you to do so.