

## Discussion: Traditional Lower Blepharoplasty: Is Additional Support Necessary? A 30-Year Review

David A. Hidalgo, M.D.  
New York, N.Y.

The authors correctly credit Dr. Thomas Rees with popularizing the skin/muscle flap approach to lower blepharoplasty. This occurred at the Manhattan Eye, Ear, and Throat Hospital over 35 years ago. I learned the technique there, as the senior author of this article probably did before me. This procedure remained a workhorse technique, with one faculty member extolling its virtues as a fast and effective procedure as late as 1998.<sup>1</sup> Working in this environment where hundreds (if not 1000) were performed yearly, I agree with the authors that the method causes few functional problems in the hands of experienced surgeons.

Practicing in this same community has allowed me to observe the long-term results of skin/muscle flap procedures in patients presenting years later for a secondary rhytidectomy or other procedure. Although many still appear quite good, there are also many that exhibit either hollowing, scleral show with rounding of the ocular aperture, or both (Fig. 1). These aesthetic issues constitute the major criticism of the technique and have led to the development of newer methods that preserve orbital fat volume, avoid middle lamellar scarring, and avoid orbicularis denervation. Although the authors prove the safety of skin/muscle flaps, they do not recognize the aesthetic morbidity associated with the technique, which is actually the larger issue.

The authors' aversion to canthopexy may be traced back to the type of canthopexies performed at the Manhattan Eye, Ear, and Throat Hospital many years ago. These were aggressive procedures that included both canthotomy and cantholysis. They were tedious to perform and sometimes resulted in late deformities caused by canthal disinsertion. Moreover, the resulting strong upward cant of the eyelid that was typical, albeit temporary, may have been acceptable for reconstructive

cases but was less appealing for use in aesthetic blepharoplasty.

Modern canthopexy methods are less destructive and complex than these earlier ones. Lateral retinacular suspension, described either as a cantholytic type by Jelks et al. or a noncantholytic type by Fagien, is relatively easy to perform.<sup>2,3</sup> Therefore, the threshold for using it is much lower in borderline situations. Moreover, it can be either temporary or more permanent based on variations in technique. Positioning of the fixation point need not be as high as that taught in earlier times. Temporary tarsorrhaphy is another option that is a simple method of providing lower eyelid support during the early postoperative period. It can also be used to control developing chemosis either at the time of the procedure or later, should it first become evident after surgery.

The authors defined the need for lower eyelid support in this study based solely on lower eyelid tone, not position. In fact, they state that "the aesthetic preference of the senior author is for a more 'wide open,' sculpted appearance of the eyes." They consider mild lower eyelid malposition with scleral show lateral to the limbus as an aesthetic concern and not a complication. Though perhaps true by strict definition, a paradigm shift occurred some time ago where a narrower ocular aperture is recognized as one of the hallmarks of the youthful norm. Therefore, modern techniques encourage a more liberal use of lid-tightening procedures to control lid position for aesthetic reasons, an intent that lies beyond the concern for preventing functional problems. Although the authors lament that some advocate performing this on every patient, a more reasonable rate of application was seen in a recent review of 248 patients where a lateral canthopexy was performed in 18 percent.<sup>4</sup>

The authors do not mention some of the associated aesthetic benefits of canthopexy. For ex-

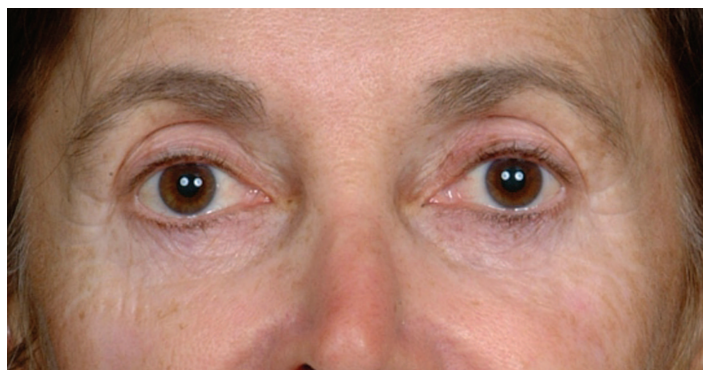*From the Division of Plastic Surgery, Weill Cornell University Medical College.*

*Received for publication January 10, 2011; accepted January 12, 2011.*

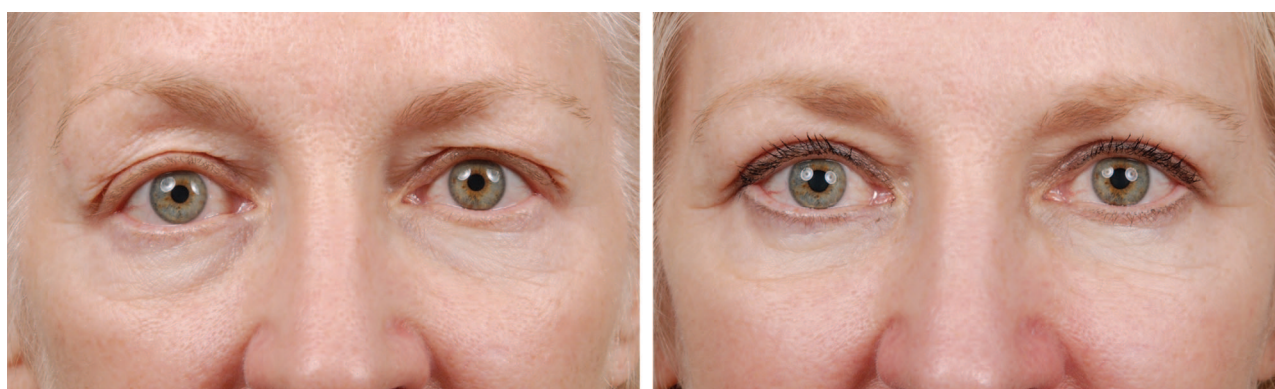
*Copyright ©2011 by the American Society of Plastic Surgeons*

DOI: 10.1097/PRS.0b013e31821742b5

**Disclosure:** *The author has no financial interest to declare in relation to the content of this Discussion or of the associated article.*



**Fig. 1.** A classic example of late hollowing and lower eyelid malposition following skin/muscle flap lower blepharoplasty.



**Fig. 2.** (Left) This patient exhibits mild lower eyelid malposition, mild excess fat, and a tear trough deformity. (Right) Treatment consisted of fat excision, transposition, and a lateral canthopexy. No skin was excised. (Adapted from Hidalgo DA. An integrated approach to lower blepharoplasty. *Plast Reconstr Surg.* 2011;127:386–395.)

ample, in some cases of mild lower eyelid malposition, the orbicularis is flaccid, mimicking a skin laxity problem. A canthopexy not only improves lower eyelid position aesthetically but also smooths out the eyelid by improving muscle tone. It can obviate the need for removing skin in this situation (Fig. 2).

One of the strengths of this article is that it is a large review of a single surgeon's experience. It is hard to imagine, though, that complete records including preoperative and postoperative photographs stretching back 30 years were available for all of the patients in the study group. The authors do not comment on the length of follow-up, although it is likely that patients manifesting either significant lower eyelid malposition or chemosis would return to the office relatively early on and be included in the analysis.

The authors do make their point convincingly within the narrow parameters of their study design. However, the low incidence of functional

complications demonstrated is probably as much a commentary on the expertise of the senior surgeon as it is a validation of the technique itself, particularly when the results are viewed from an aesthetic perspective that is somewhat at odds with current thinking.

*David A. Hidalgo, M.D.*  
655 Park Avenue  
New York, N.Y. 10065  
dh@drdavidhidalgo.com

#### REFERENCES

1. Aston S. Skin-muscle flap lower lid blepharoplasty. *Clin Plast Surg.* 1998;15:305–308.
2. Jelks GW, Glat PM, Jelks EB, Longaker MT. The inferior retinacular lateral canthopexy: A new technique. *Plast Reconstr Surg.* 1997;100:1262–1270; discussion 1271–1275.
3. Fagien S. Algorithm for canthopexy: The lateral retinacular suspension: A simplified suture canthopexy. *Plast Reconstr Surg.* 1999;103:2042–2053; discussion 2054–2058.
4. Hidalgo DA. An integrated approach to lower blepharoplasty. *Plast Reconstr Surg.* 2011;127:386–395.